

Crisis averted: a patient in cardiopulmonary arrest

James Keeton BS, Saranapoom Klomjit MD, Mamoun Bashir MD

ABSTRACT

Neuromuscular diseases are rare causes of acute hypercapnic respiratory failure due to respiratory muscle weakness and can be life-threatening if not recognized. We report a case of a 35-year-old man with worsening dyspnea, non-productive cough, and fever presenting in cardiopulmonary arrest requiring intubation and mechanical ventilation. After work-up for neuromuscular disease with a positive acetylcholine receptor antibody test, the source of his respiratory failure was discovered to be myasthenia gravis. He improved with acetylcholinesterase inhibitors, corticosteroids, and plasmapheresis therapy but had a long complicated hospital course. Computed tomography of the chest with intravenous contrast revealed an anterior mediastinal mass, which was later resected and confirmed to be a thymoma.

Key words: myasthenia gravis, respiratory failure, thymoma

INTRODUCTION

Myasthenia gravis is an autoimmune neuromuscular disease causing muscle weakness, characteristically worse at the end of the day and with repetitive muscle use. Myasthenia gravis has a bimodal distribution with 4:1 female predominance before the age of 55, and equal distribution of affected males and females after age 55.¹ There are two forms of the disease: generalized and ocular. The generalized form is the most common type, comprising 85% of cases, and usually includes ocular symptoms; however, the pure ocular form can become generalized.¹ Ocular symptoms are commonly seen due to consistent eye use throughout the day. Respiratory failure is a potentially fatal complication of myasthenia gravis called myasthenic crisis.¹ This complication occurs in 15-20% of all cases and requires intubation in 66 to 90% of patients.¹ Myasthenic crisis is the initial pre-

sentation in 20% of patients with myasthenia gravis.¹

CASE

A 35-year-old Hispanic man with no significant medical history presented with worsening dyspnea, fever, and a non-productive cough for three weeks. He had a right lower lobe infiltrate on chest x-ray and leukocytosis. He was admitted and empirically treated for community-acquired pneumonia with intravenous levofloxacin. He did not improve, and computed tomography of the chest showed an anterior mediastinal mass compressing part of the superior vena cava (Figure 1). He was transferred to our facility for a higher level of care. During the airlift, the patient was very anxious and received three doses of lorazepam. Upon arrival, he suffered cardiorespiratory arrest, was intubated, and required cardiopulmonary resuscitation. Initial arterial blood gas showed a pH of 6.74, a PaCO₂ of 193 mm Hg, and a HCO₃⁻ of 25 mEq/L. Cardiac diagnoses were ruled out, and his urine drug screen was negative. Antibiotic coverage was expanded to include piperacillin/tazobactam and vancomycin for his pneumonia. Antibody profiles, including

Corresponding author: James Keeton BS
Contact Information: james.keeton@ttuhsc.edu
DOI: 10.12746/swrccc2016.0414.187

acetylcholine receptor (AChR) antibody and muscle-specific tyrosine kinase (MuSK) antibody, were sent to a reference laboratory. Extubation was attempted several days later but was unsuccessful due to severe dyspnea and agitation. He subsequently required a tracheostomy. On neurological examination two weeks post arrest, the patient was unable to raise his arms above his head; he had intermittent myoclonic jerking of his upper extremities, hyperreflexia, and positive Babinski reflexes bilaterally. Anoxic encephalopathy with myoclonus secondary to the respiratory arrest was considered the likely diagnosis. Eventually, the antibody profile returned as positive for AChR antibodies and negative for MuSK antibodies; he was started on pyridostigmine, prednisone, and five days of plasmapheresis. After three days of plasmapheresis, the patient became much more awake and alert. Additional history from his family revealed that he was experiencing ptosis of his left eye one month prior to presentation. Thymectomy was performed, and the histology was consistent with a thymoma. His course was complicated by ischemic acute tubular necrosis, *Pseudomonas* pneumonia, urinary tract infection, agitation, percutaneous endoscopic gastrostomy, and a prolonged course in the intensive care unit. He was eventually discharged to a long-term acute care facility.

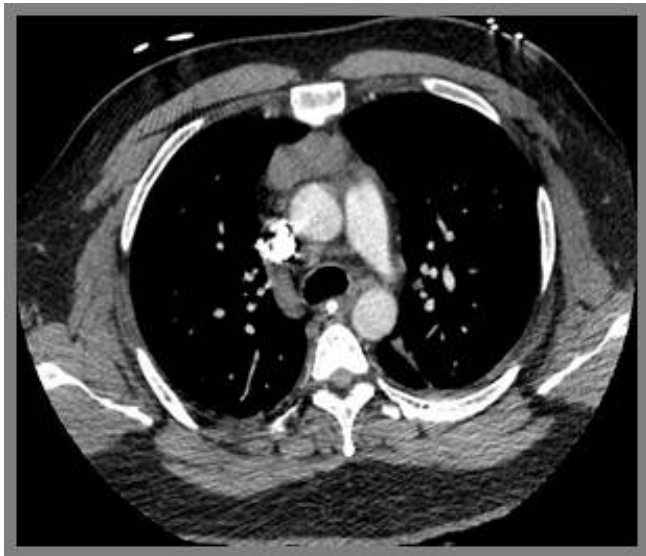


Figure 1: Anterior mediastinal mass on CT of chest with IV contrast

DISCUSSION

This case demonstrates the importance in monitoring the respiratory status of patients with myasthenia gravis since they can quickly decompensate and have a respiratory arrest. A significant percentage (15-20%) of patients with myasthenia gravis develop respiratory failure, most commonly within the first year of diagnosis.¹ As in this case, respiratory infections commonly precipitate the crisis.¹ Furthermore, patients with myasthenia gravis who initially present with respiratory complaints can present difficult diagnostic challenges. Improved ventilator support has significantly lowered the mortality for myasthenic crisis to approximately 5%.² The parameters recommended for monitoring include the vital capacity (VC) and the negative inspiratory force (NIF).³ A VC less than 1 L, or 20-25 mL/kg, or a NIF less than 20 cm H₂O signifies considerable respiratory muscle weakness and usually indicates the need for intubation and mechanical ventilation.¹ However, clinical signs of impending respiratory failure, such as recruitment of accessory muscles and a weak cough, should also guide decisions about the need for respiratory support. Short-term treatment of myasthenic crisis includes either intravenous immunoglobulin at 400 mg/kg/day for five days or plasma exchange every other day for ten days.¹ A recent literature review critically appraised one head-to-head comparison of intravenous immunoglobulin and plasma exchange in patients with worsening myasthenia gravis.⁵ This study reported that both treatment approaches had similar outcomes in the treatment of moderate to severe myasthenia gravis, but the study did not include patients in myasthenic crisis.⁵ Currently, there is not enough high quality evidence to support the use of any specific therapy over others in myasthenic crisis.⁴ Long-term immunosuppression, most commonly with corticosteroids, also improves symptoms and reduces exacerbations.¹ In conclusion, it is essential to monitor the respiratory status of patients with myasthenia gravis and keep a low threshold for intubation due to the possibility of respiratory failure. In addition, the possibility of myasthenia gravis should be considered in patients presenting with acute hypercapnic

respiratory failure.

Author Affiliation: James Keeton is a medical student at Texas Tech University Health Sciences Center in Lubbock, TX. Saranapoom Klomjit is a resident in Internal Medicine at TTUHSC in Lubbock, TX. Mamoun Bashir is a nephrologist at TTUHSC in Lubbock, TX.

Received: 01/18/2016

Accepted: 04/01/2016

Reviewers: Mark Sigler MD

Published electronically: 04/15/2016

Conflict of Interest Disclosures: none

REFERENCES

1. Wendell LC, Levine JM. Myasthenic crisis. *The Neurohospitalist* 2011; 1(1):16-22. doi:10.1177/1941875210382918.
2. Alsheklee A, Miles JD, Katirji B, Preston DC, Kaminski HJ. Incidence and mortality rates of myasthenia gravis and myasthenic crisis in US hospitals. *Neurology* 2009; 72(18): 1548-554. doi: 10.1212/WNL.0b013e3181a41211.
3. Prigent H, Orlikowski D, Letilly N, Falaize L, Annane D, Sharshar T, Lofaso F. Vital capacity versus maximal inspiratory pressure in patients with Guillain-Barré syndrome and myasthenia gravis. *Neurocritical Care* 2011; 236-39. doi: 10.1007/s12028-011-9575-y.
4. Godoy DA, Mello LJ, Masotti L, Di Napoli M. The myasthenic patient in crisis: an update of the management in neurointensive care unit. *Arquivos de Neuro-Psiquiatria*, 2013; 71(9A), 627-639. doi: 10.1590/0004-282X20130108.
5. Dhawan PS, Goodman BP, Harper CM, Bosch PE, Hoffman-Snyder CR, Wellik KE, Wingerchuk DM, Demaerschalk BM. IVIG versus PLEX in the treatment of worsening myasthenia gravis: what is the evidence?: a critically appraised topic. *Neurologist* 2015; 19(5):145-148. doi: 10.1097/NRL.0000000000000026.