

## Tic-“tack”-toe, out I go: A strategic implementation of flexible bronchoscopy in the removal of an aspirated thumbtack

Saria Tasnim MD, Balaji Mohanakrishnan MD, Nandini Ray MD, Manish Patel MD

### ABSTRACT

*Thumbtack aspiration is a medical emergency as the sharp end poses a risk of injuring the respiratory tract and potentially causing fatal complications. Its removal can be difficult, even under bronchoscopy guidance, as the sharp end can potentially lead to bronchial mucosal tears and perforation. We present a case of 16-year-old male who was admitted following the unintentional ingestion of a thumbtack that was removed using flexible bronchoscopy. These sharp metal objects are commonly removed using rigid bronchoscopy, but removal by flexible bronchoscopy, although challenging, is still possible.*

**Keywords:** Foreign body; flexible bronchoscopy; thumbtack

### INTRODUCTION

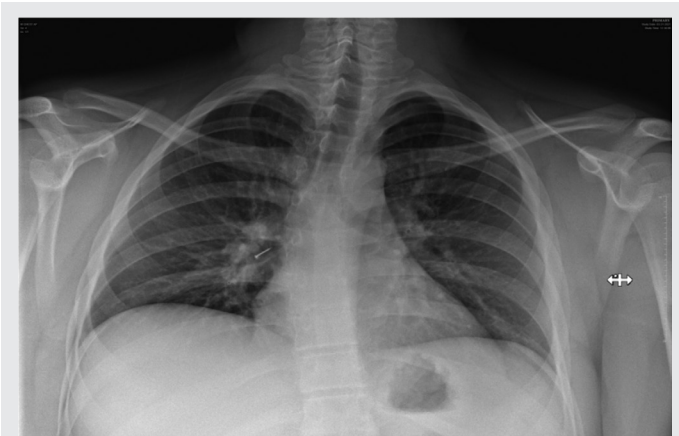Unintentional foreign body (FB) aspiration usually occurs during childhood. However, it can happen to anyone irrespective of age, especially in the presence of a neurological or neuromuscular motility disorder. Aspirated materials can be expelled spontaneously, by vigorous coughing, or by the Heimlich maneuver. However, aspiration of sharp objects, such as thumbtacks, can be serious, and their removal can be quite challenging and technically demanding due to the risk of airway perforation. Many cases in the literature demonstrate the advantages of rigid bronchoscopy over flexible bronchoscopy; these include improve ventilation of the patient, better visualization of the field, and easier manipulation of the FB, thereby allowing this method to serve as the standard of care in removing FBs.<sup>1,2</sup> However, several case reports have shown that flexible bronchoscopy is a safe and effective method of removing FB but depends on the physician's experience and the presence of improved accessories.<sup>3</sup>

**Corresponding author:** Saria Tasnim  
**Contact Information:** Saria.Tasmin@ttuhsc.edu  
**DOI:** 10.12746/swrccc.v11i46.1083

### CASE

A 16-year-old male with a history of anxiety and attention-deficit/hyperactivity disorder was admitted to the hospital following aspiration of a thumbtack. The patient stated that he had a thumbtack in his mouth when he coughed and subsequently aspirated it. His only complaints were throat pain and dry cough on presentation, but he denied fever, dyspnea, chest pain, or hemoptysis. On admission, he was hemodynamically stable with normal oxygen saturation on room air, and his lab tests were normal. A chest x-ray demonstrated a radiopaque FB in the right lower lobe bronchus measuring 1 centimeter (Figure 1).

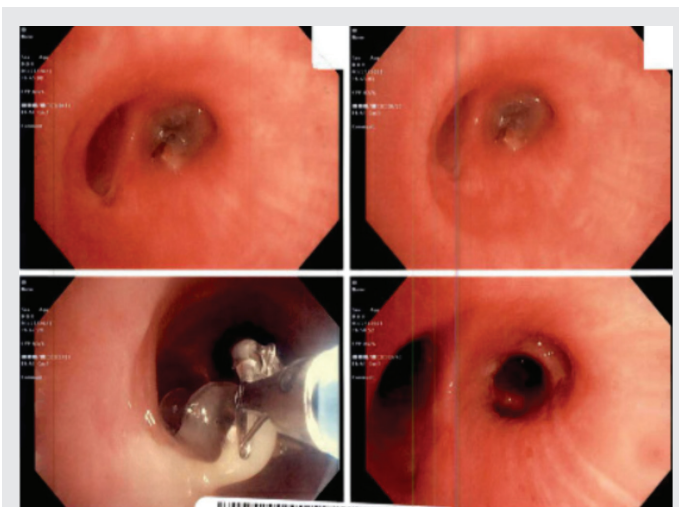
The patient was monitored with continuous pulse oximetry, and pulmonology was consulted for FB removal by flexible bronchoscopy. In addition, thoracic surgery was called as a backup for lobectomy if the FB became dislodged distally. Due to knowledge of the type of FB aspirated, a simulation exercise was performed in the operating room prior to the procedure using a thumbtack, flexible endoscope, and size 9 endotracheal (ET) tube. During this simulation, it was determined that the thumbtack could not be removed using the ET tube regardless of the angle used to access the FB, so a decision was taken to



**Figure 1.** Chest x-ray of the patient demonstrating radiopaque FB in the right lower lobe bronchus.

remove the FB along with the ET tube after securing the sharp end inside the ET tube. Likewise, the simulation demonstrated that forceps would be sufficient to grasp the FB, but additional FB retrieval tools were available if necessary.

The patient was subsequently taken to the operating room, intubated, and anesthetized under general anesthesia with a size 9 ET tube. The flexible endoscope was introduced into the right lung, and the FB was found at the origin of the right lower lobe bronchus surrounded by secretions (Figure 2). Forceps



**Figure 2.** Bronchoscopic image showing FB at right lower lobe bronchus.

were introduced, the sharp end of the thumbtack was grasped, and the FB was withdrawn up to the level of the ET tube. However, the FB was dislodged from the grip of the forceps but stayed in the lower end of the trachea as the patient was under general anesthesia. The sharp end of the FB was grabbed again and secured inside the ET tube. After ensuring no injury to surrounding region, the ET tube, endoscope, and FB were removed. The patient was reintubated immediately, and the flexible bronchoscope was re-introduced. Both lungs were examined again up to the level of the segmental bronchi, no other FB elements were found, and all the secretions were suctioned out. The patient tolerated the procedure well, was stable on room air overnight, and was discharged home the next day.

## DISCUSSION

Most aspirated FBs occur in children and are less common in adults. Food is the most commonly aspirated FB, and metal objects are generally not aspirated intentionally.<sup>4</sup> Adult FB aspirations are less common than in children but have a higher percentage of inorganic aspiration. The most common symptoms are cough, tachypnea, wheezing, and/or stridor in both adults and children. Dyspnea is a less common chief complaint. Foreign body aspiration can lead to rapid respiratory distress and possibly respiratory failure. Signs of respiratory distress include abdominal or chest wall retractions, cyanosis, tripodding, and altered mental status. The size and location of the FB will determine the degree of respiratory distress. Left untreated, aspiration of organic material can lead to fever, persistent cough, acute respiratory distress syndrome, and pneumonia.<sup>5</sup> Nonorganic material, such as plastic or metal, can cause infection or perforation, thereby leading to pneumothorax.

A plain chest x-ray is the first diagnostic test to determine whether a radiopaque FB is present. However, since most aspirated FBs in children are organic material, these are often radiolucent. Other x-ray findings seen in aspiration include hyperinflated lungs, atelectasis, and a mediastinum shift. Late x-ray findings include pneumonia, abscesses, and

bronchiectasis.<sup>6</sup> Computed tomography can detect FB with almost 100% sensitivity and specificity.

Rigid bronchoscopy is the preferred method of diagnosis and removal of FBs. Bronchoscopy is successful in removing FB in 95% of cases with a concomitant 1% complication rate.<sup>7</sup> Complications include airway perforation, retained FB, and increasing distal obstruction. Despite these complications, a case report in the literature demonstrated the use of flexible bronchoscopy for successful removal of a thumbtack.<sup>3</sup> The main difficulty in removing a thumbtack is that its sharp edge tends to be deeply lodged within the bronchial mucosa, and the limited space within the bronchial lumen makes it difficult to safely remove via forceps. Additionally, another major limitation of removing a thumbtack using a flexible bronchoscope is that the tack could be dislodged from the forceps, which occurred in the case presented here. However, fewer chest movements during the procedure due to the induction of general anesthesia prevented the thumbtack to be dislodged distally. This case also demonstrates that if the type of foreign body is known, a simulation exercise prior to performing the procedure can be helpful in developing a strategy to remove the FB as it is a relatively uncommon procedure. A larger FB can be successfully removed using an ET tube, and if properly secured, both the FB and ET tube can be removed simultaneously under direct visualization.

## CONCLUSION

The presence of FBs in the airways can lead to a potentially life-threatening event. Although rigid bronchoscopy is the preferred method of diagnosis and removal of a FB, flexible bronchoscopy can be successfully used to remove sharp objects such as a thumbtack under general anesthesia if a strategy is

formulated prior to the procedure and a backup plan is in place.

**Article citation:** Tasnim S, Mohanakrishnan B, Ray N, Patel M. Tic-“tack”-toe, out I go: A strategic implementation of flexible bronchoscopy in the removal of an aspirated thumbtack. *The Southwest Respiratory and Critical Care Chronicles* 2023;11(46):56–58

**From:** Department of Internal Medicine, Texas Tech University Health Sciences Center, Amarillo, Texas

**Submitted:** 9/11/2022

**Accepted:** 12/26/2022

**Conflicts of interest:** none

This work is licensed under a Creative Commons Attribution-ShareAlike 4.0 International License.

## REFERENCES

1. Ludemann JP, Riding KH. Choking on pins, needles and a blowdart: aspiration of sharp, metallic foreign bodies secondary to careless behavior in seven adolescents. *Int J Pediatr Otorhinolaryngol* 2007;71(2):307–310.
2. Paradis TJ, Dixon J, Tieu BH. The role of bronchoscopy in the diagnosis of airway disease. *J Thorac Dis* 2016;8(12):3826–3837.
3. Copeland SW, Sigler M, R. Alalawi R. Thumbtack aspiration: a unique bronchoscopic challenge. Doi: 10.1164/ajrcmconference.2016.193.1\_MeetingAbstracts.A3286
4. Limper AH, Prakash UB. Tracheobronchial foreign bodies in adults. *Ann Intern Med* 1990;112(8):604–609.
5. Blazer S, Naveh Y, Friedman A. Foreign body in the airway. A review of 200 cases. *Am J Dis Child* 1980;134(1):68–71.
6. Al-Majed SA, Ashour M, al-Mobeireek AF, et al. Overlooked inhaled foreign bodies: late sequelae and the likelihood of recovery. *Respir Med* 1997;91(5):293–296.
7. Sersar SI, Rizk WH, Bilal M, et al. Inhaled foreign bodies: presentation, management and value of history and plain chest radiography in delayed presentation. *Otolaryngol Head Neck Surg* 2006;134(1):92–99.