

Necrotizing Soft Tissue Infections

Chance Witt, MD, Sharmila Dissanaik, MD

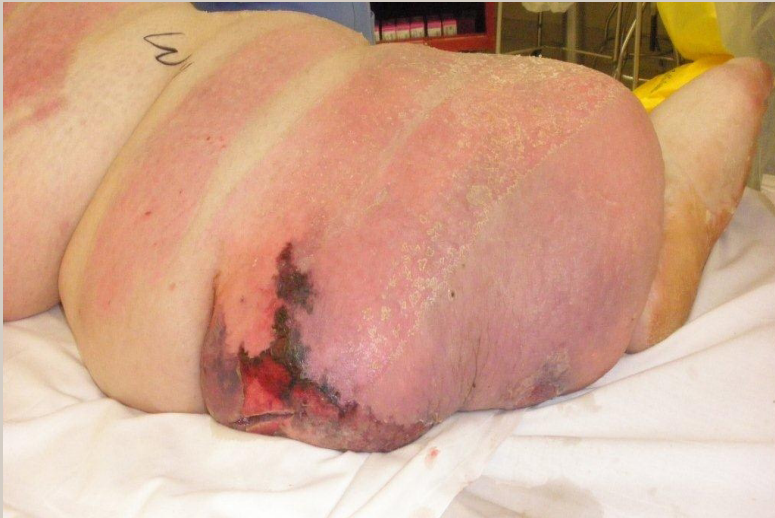

Figure 1 Left leg with necrotizing soft tissue infections.

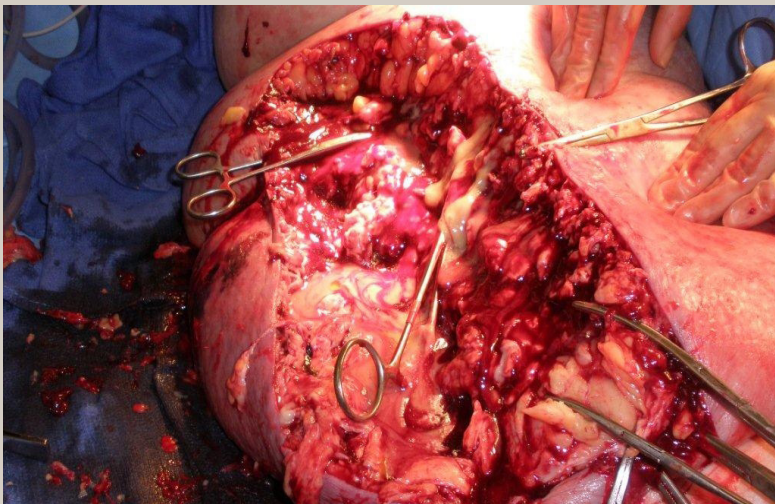


Figure 2 Debridement of the left leg : showing purulence.

Author Affiliation: Chance Witt, MD, is a resident in General Surgery at the Mayo School of Graduate Medical Education in Rochester, MN. Sharmila Dissanaik, MD, is a trauma and burn surgeon in the Department of Surgery at TTUHSC in Lubbock, TX.
Received: 9/16/2012
Accepted: 12/19/2012
Reviewers: Kenneth Nugent, MD; Richard Winn, MD
DOI: 10.12746/swrccc2013.0101.009

This is a very heavy woman who initially had an Necrotizing Soft Tissue Infection (NSTI) of the right leg which was extensively debrided and skin grafted and healed well, then presented 2 months later with a new NSTI of the left leg.

References

1. Wong CH, Chang HC, Pasupathy S, et al. Necrotizing fasciitis: clinical presentation, microbiology, and determinants of mortality. *J Bone Joint Surg Am* 2003; 85:1454-60.