

Hemopericardium in chronic kidney disease: An uncommon manifestation of pericarditis with a bloody pericardial effusion

Jackson Martin BS, Brian Williams MD, Mohammed Otahbachi MD

ABSTRACT

Patients with end-stage renal disease are at increased risk for the development of uremic pericarditis or dialysis-associated pericarditis, and either comorbidity can be complicated by pericardial effusion. Patients with end-stage renal disease complaining of dyspnea and chest pain demand a robust differential diagnosis, which can delay an appropriate intervention. Here we describe a patient with pericarditis and hemopericardium causing symptomatic pericardial effusion.

Keywords: Uremic hemopericardium, uremic pericarditis, pericardiocentesis

INTRODUCTION

Comorbidities of chronic kidney disease include uremic pericarditis and dialysis-associated pericarditis. The presentation for both subtypes of pericarditis is similar, and the differentiation is typically determined by timeframe from starting dialysis. Uremic pericarditis typically occurs before or within 8 weeks of starting dialysis, and dialysis-associated pericarditis occurs after starting dialysis.¹

Uremic toxins presumably cause pericardial inflammation in both uremic and dialysis-associated pericarditis although the exact etiology remains unknown. Typically, either subtype of pericarditis responds to appropriate hemodialysis, and non-responsive cases respond to intensive hemodialysis. Additional treatment, such as corticosteroids, NSAIDs and pericardiocentesis, are used in hemodialysis-refractory cases.¹

CASE

A man in his mid-forties presented to the hospital with shortness of breath. On admission, the patient

reported he had experienced constant and worsening shortness of breath for the past four weeks, which increased with minimal exertion. His shortness of breath abruptly worsened over the past three days, which prompted him to come to the emergency room. In addition, the patient reported severe, left-sided, stabbing chest pain, which was exacerbated by breathing and radiated to his back. He reported coughing up white mucus, a feeling of abdominal fullness, nausea, and an episode of emesis. He denied fever and chills. The patient reported that he has dialyzed at home for over two years with continuous ambulatory peritoneal dialysis. He said he had been compliant with treatment, although the patient did not regularly see a primary care physician, so routine laboratory tests were not available.

His vital signs included a temperature of 35.6°C, a blood pressure of 166/110 mmHg, a heart rate of 112 beats/minute, a respiratory rate of 13 breaths/minute, and a peripheral capillary oxygen saturation of 99% on 2 liters per minute by nasal cannula. The examining physician noted him to be ill-appearing and obese. His cardiac examination was unremarkable without lower extremity edema or elevated jugular venous pressure. His pulmonary examination showed bilateral rales and increased respiratory effort; his chest wall had no tenderness on palpation. His abdominal examination was unremarkable.

Corresponding author: Jackson Martin
Contact Information: Jackson.Martin@ttuhsc.edu
DOI: 10.12746/swrccc.v11i47.1147

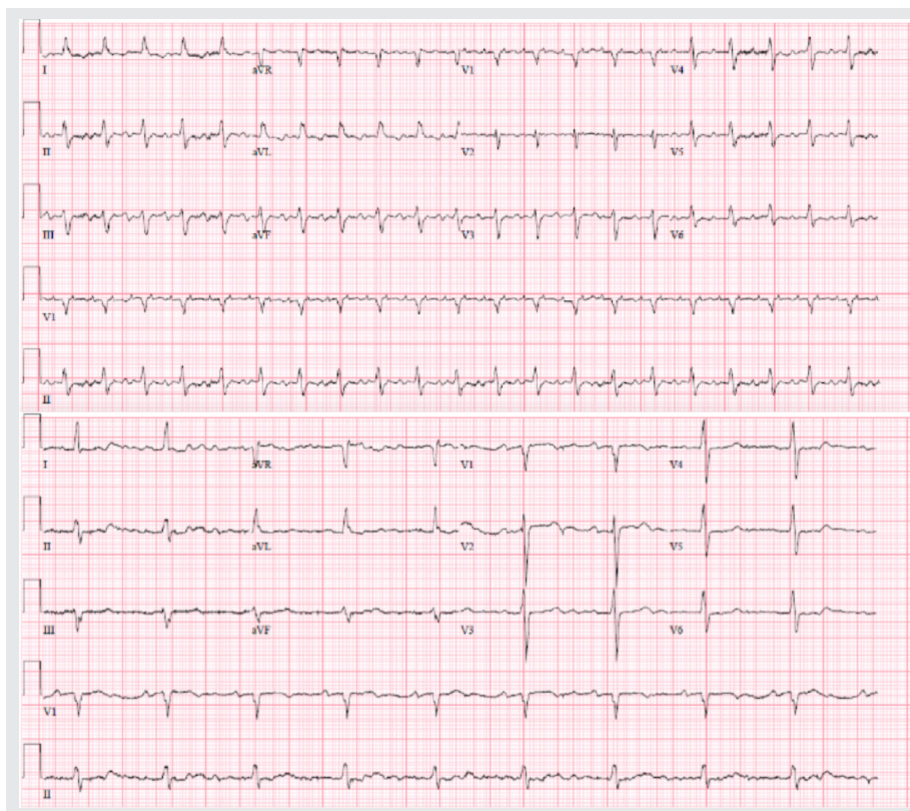


Figure 1. Electrocardiograms. ECG on admission (top) demonstrating diminished electrical voltage in precordial leads compared with ECG obtained two months prior (bottom).

The patient’s prior history included end-stage renal disease (ESRD), congestive heart failure, obstructive sleep apnea, and hypertension. His home medications included diltiazem, furosemide, carvedilol, calcium acetate, and clonazepam.

The differential diagnosis for a dialysis patient with chest pain and dyspnea includes dialysis-related fluid overload, dialysis-associated pericarditis, uremic pericarditis, decompensated congestive heart failure, acute coronary syndrome, pericarditis with effusion, pneumonia, and pulmonary embolism. These possibilities led to the following investigation.

His electrocardiogram (ECG) demonstrated 2:1 atrial flutter and no conclusive findings for pericarditis or pericardial effusion, such as diffuse ST-elevation, PR depression, or electrical alternans. However, the voltage of the patient’s ECG had decreased compared with an ECG obtained two months earlier (Figure 1). The patient’s complete blood count showed leukocytosis (Table 1), and the comprehensive metabolic panel showed a significantly elevated BUN, high creatinine, high phosphorus, metabolic acidosis, low albumin, and

low sodium (Table 2), suggesting inadequate dialysis. The patient’s high sensitivity troponin I was elevated to 178 ng/L. The chest x-ray showed an enlarged cardiac silhouette and bilateral pleural effusions (Figure 2).

Table 1. Complete Blood Counts

WBC	16.01 k/ μ L
RBC	3.72 m/ μ L
Hemoglobin	11.4 g/dL
Hematocrit	34.0 %
MCV	91.4 fl
MCH	30.6 pg
MCHC	33.5 g/dL
RDW-CV	18.1 %
Platelets	233 k/ μ L
Platelet Estimate	Normal
MPV	10.3 fl

Patient’s complete blood counts demonstrating leukocytosis on admission to the hospital.

Table 2. Comprehensive Metabolic Panel

Na	130 mmol/L
K	4.8 mmol/L
Chloride	95 mmol/L
Carbon dioxide	16 mmol/L
Anion Gap	19 mmol/L
Glucose	112 mg/dL
BUN	123 mg/dL
Creatinine	16.60 mg/dL
Albumin	2.7 g/dL
Total Protein	6.8 g/dL
eGFR	3 mL/min
Calcium	6.0 mg/dL
Phosphorus	8.0 mg/dL
Alk Phos	176 U/L
ALT	98 U/L
AST	19 U/L
Total Bili	1.1

Patient’s comprehensive metabolic panel with abnormalities suggestive of poor dialysis. The low albumin is also an indication of potential need to drain the effusion.

The patient started hemodialysis and exhibited minimal improvement after two days. An echocardiogram (ECHO) showed an ejection fraction of 30% with pericardial effusion (Figure 3). Hemodialysis was continued for two more days since there was no evidence of tamponade. This was now day four since presentation, and the patient’s clinical condition continued to deteriorate. The patient now required CPAP to maintain adequate oxygen saturation. A bedside ECHO was repeated and demonstrating an increasing pericardial effusion (Figure 3). The patient’s blood pressure was 133/90 mmHg at this time, which would not support the diagnosis of tamponade.

The patient was transferred to the medical intensive care unit for pericardiocentesis and to manage his clinically deteriorating condition. An apical pericardiocentesis was performed and 1400 ccs of grossly sanguineous fluid was drained from the pericardium (Figure 4). A drain was placed, and an additional 600 ccs were drained over the next 24 hours. The patient was started on colchicine to reduce pericardial inflammation. An ECHO repeated after the procedure showed a normalized ejection fraction of 60%. The patient’s shortness of breath and chest pain improved, and he no longer required CPAP to support gas exchange. Cytology of the pericardial fluid showed 862,000 red blood cells/μL and 3,498 white blood cells/μL with 90%

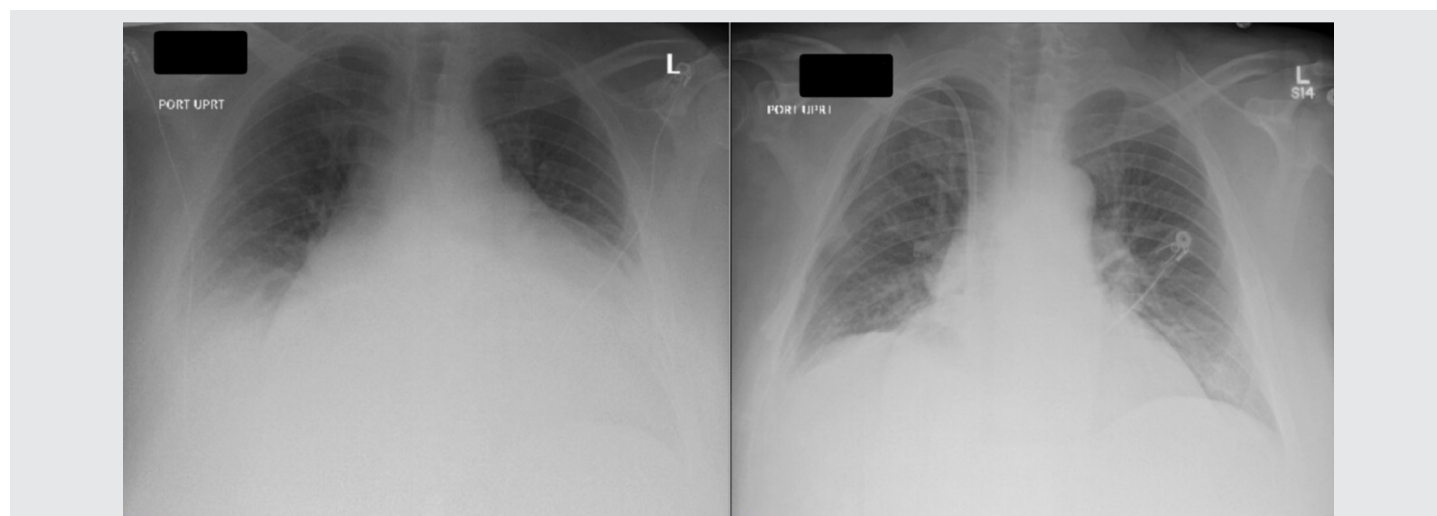

Figure 2. X-ray on admission and after pericardiocentesis.

X-ray on admission (left) demonstrating enlarged cardiac silhouette secondary to effusion and X-ray before discharge showing improvement of cardiomegaly and improvement of pleural effusion.

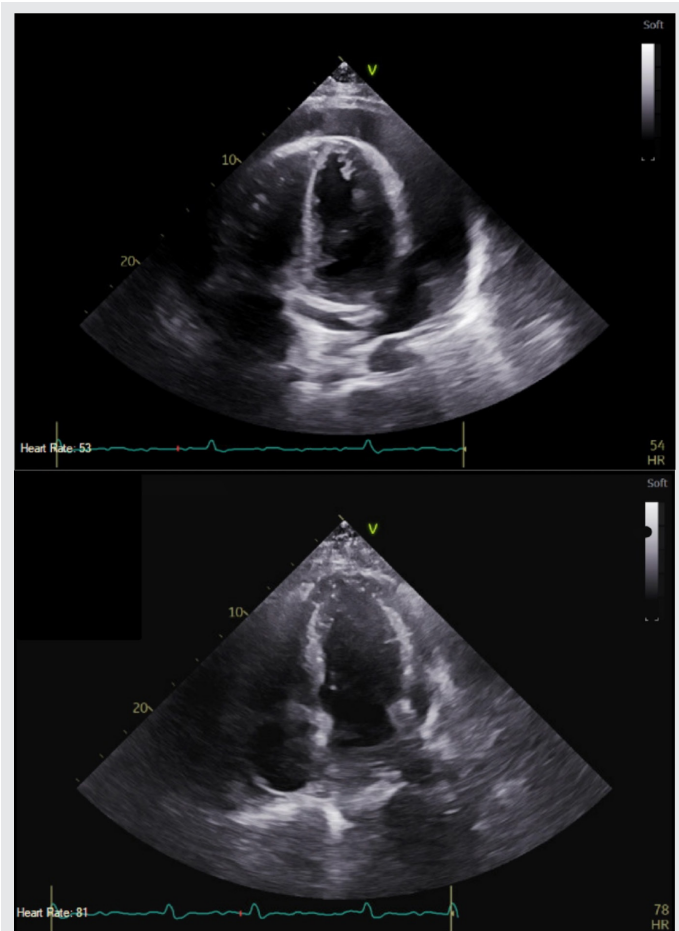


Figure 3. Echocardiogram before and after pericardiocentesis. Echocardiogram shows pericardial effusion before (top) and after (bottom) pericardiocentesis. The patient’s ejection fraction improved from 30% to 60% after the drainage.

neutrophils. A culture and smear of the pericardial fluid demonstrated thrombotic debris with neutrophils and was negative for microorganisms, including a negative PCR for tuberculosis, and malignant cells.

DISCUSSION

Pericarditis is a well-known complication of ESRD. The two most likely causes are uremic pericarditis and dialysis-associated pericarditis. Uremic pericarditis typically occurs before initiating dialysis or within

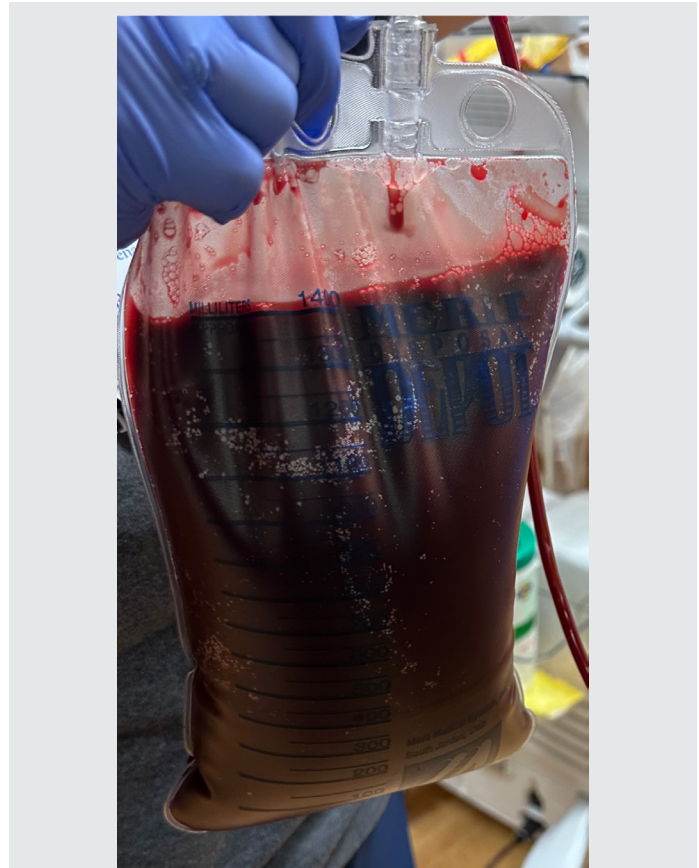


Figure 4. Pericardial fluid. 1400 ccs of sanguineous fluid drained initially from pericardiocentesis.

8 weeks of initiation, while dialysis-associated pericarditis typically occurs after 8 weeks of the initiation of dialysis.¹ Our patient had dialysis-associated pericarditis; however, the metabolic disorders in this case made this distinction less clear. It is possible insufficient dialysis caused by noncompliance or poor continuous ambulatory peritoneal dialysis resulted in toxic metabolite accumulation, and clinically the patient’s status represented uremic pericarditis more than dialysis-associated pericarditis.

Uremic and dialysis-associated pericardial effusions are frequently asymptomatic or cause nonspecific symptoms, such as shortness of breath, orthopnea, chest pain, and compressive symptoms, like nausea, dysphagia, and hoarseness. Identifying pericarditis in dialysis patients can be challenging since patients with ESRD

complicated by pericarditis present with varying degrees of symptoms, laboratory findings, and ECG abnormalities. Troponin has been documented as elevated in 32% of cases of pericarditis.² Leukocytosis has also been documented in 40–60% of cases of pericarditis.³ Although blood urea nitrogen was elevated in this patient, it has been reported that there is no statistically significant difference between elevated blood urea nitrogen in patients with and without uremic dialysis-associated pericarditis.⁴ ECG findings consistent with pericarditis are found in 60% of patients; however, diffuse ST elevations were not noted on our patient's ECG.⁵ One study has reported that a serum albumin less than 3.1 g/dL coupled with a high estimated volume pericardial effusion can be predictive in determining a patient need's for pericardiocentesis.⁶ Another study predicted factors associated with intensive dialysis failure in uremic pericarditis. Our patient presented with three of those factors including a white blood count over 15 k/ μ L, rales, and a large pericardial effusion on an ECHO.⁷

The recommended treatment for patients with pericarditis without tamponade and renal failure includes hemodialysis as a first line treatment. Intensive dialysis should be considered in non-responsive patients. Pericardiocentesis, NSAIDs, and corticosteroids should be considered in refractory cases. Our patient received colchicine, which should be used cautiously or not at all in patients with renal failure. Other treatments, such as immunosuppressive drugs and intravenous immunoglobulins, can be used in refractory cases.¹

Last, there are few reports of dialysis-associated pericarditis causing hemopericardium, which was observed in our patient, and the mechanism causing hemopericardium versus straw-colored fluid effusion, which is more commonly observed in dialysis-associated pericardial effusion, is poorly understood. We propose two possible mechanisms for this presentation. Either this patient did have uremic pericarditis, which is more likely to cause hemopericardium than dialysis-associated pericarditis, or another mechanism such as hemorrhagic conversion of serous pericardial effusion by an anticoagulant is responsible. Our patient was taking enoxaparin while hospitalized, and there are cases of anticoagulant medications such as heparin causing hemopericardium in patients

on dialysis.⁸ Further research should consider whether blood in a dialysis-associated pericardial effusion is indicative of a more severe disease course requiring interventional care.

FOLLOW UP

The following day the patient was comfortable without oxygen supplementation. His ECG was repeated and demonstrated a return to baseline in voltage across all leads compared with the ECG obtained at presentation and a return to sinus rhythm. His white blood cell count was in a normal range within a few days of pericardiocentesis. He continued to undergo hemodialysis, and the decision was ultimately made to remove his peritoneal catheter since it wasn't functioning sufficiently. The patient was discharged in stable condition eight days later.

CONCLUSIONS

We describe a case of pericarditis with hemopericardium. Typically, dialysis-associated pericarditis with effusion causes a straw-colored fluid accumulation, and the clinical condition will improve with appropriate dialysis. Intervention should be considered to alleviate patient symptoms if there is no improvement with hemodialysis alone. Clinicians should consider alternative therapies, such as pericardiocentesis, earlier in treatment when the pericarditis is complicated by a large effusion. Finally, our patient was noted to have significant blood in his pericardial effusion, and the physiologic mechanism behind the presentation is poorly understood.

Article citation: Martin J, Williams B, Otahbachi M. Hemopericardium in chronic kidney disease: An uncommon manifestation of pericarditis with bloody pericardial effusion. *The Southwest Respiratory and Critical Care Chronicles* 2023;11(47):55–60

From: School of Medicine, Texas Tech University Health Sciences Center, Covenant Campus, Lubbock, Texas

Submitted: 2/8/2023

Accepted: 4/2/2023

Conflicts of interest: none

This work is licensed under a Creative Commons Attribution-ShareAlike 4.0 International License.

REFERENCES

1. Adler Y, Charron P, Imazio M, et al. 2015 ESC guidelines for the diagnosis and management of pericardial diseases. *Eur Heart J* 2015;36(42):2921–2964. doi:10.1093/eurheartj/ehv318
2. Imazio M, Demichelis B, Cecchi E, et al. Cardiac troponin I in acute pericarditis. *J Am Coll Cardiol* 2003;42(12):2144–8. doi: 10.1016/j.jacc.2003.02.001.
3. Rostand SG, Rutsky EA. Pericarditis in end-stage renal disease. *Cardiol Clin* 1990;8(4):701–7.
4. Dad T, Sarnak MJ. Pericarditis and pericardial effusions in end-stage renal disease. *Semin Dial* 2016;29(5):366–73. doi:10.1111/sdi.12517.
5. Rehman KA, Betancor J, Xu B, et al. Uremic pericarditis, pericardial effusion, and constrictive pericarditis in end-stage renal disease: Insights and pathophysiology. *Clin Cardiol* 2017; 40:839–846. <https://doi.org/10.1002/clc.22770>
6. Bataille S, Brunet P, Decourt A, et al. Pericarditis in uremic patients: serum albumin and size of pericardial effusion predict drainage necessity. *J Nephrol* 2015;28(1):97–104. doi:10.1007/s40620-014-0107-7.
7. De Pace NL, Nestico PF, Schwartz AB, et al. Predicting success of intensive dialysis in the treatment of uremic pericarditis. *Am J Med* 1984 Jan;76(1):38–46. doi:10.1016/0002-9343(84)90742-3.
8. Su H-M, Voon W-C, Chu C-S, et al. Heparin-induced cardiac tamponade and life-threatening hyperkalemia in a patient with chronic hemodialysis. *Kaohsiung J Med Sci* 2005;21(3): 128–133. doi:10.1016/S1607-551X(09)70289-X