

# COVID-19 infection with serial bilateral pneumothoraces

Rosa Ragozzino MD, Antonella Risoli MD, Anna Maria Martone MD, Vincenzo Brandi MD,  
Rosa Liperoti MD, Francesco Landi MD

## ABSTRACT

**Background:** Coronavirus disease 2019 (COVID-19) is most frequently associated with a mild presentation of fever, cough, and shortness of breath. Typical radiographic findings in severe COVID-19 infection are bilateral ground-glass opacities on computed tomography (CT) scans. Bilateral pneumothorax is a rare complication of COVID-19. Among observational studies, the incidence of pneumothorax is low at 0.3% in hospitalized COVID-19 patients. However, the incidence of pneumothorax increases to 12.8–23.8% in patients requiring invasive mechanical ventilation.

**Case:** This case report describes a previously healthy 52-year-old man who had recurrent pneumothoraces. He had five separate episodes of bilateral pneumothoraces during a two-month infection with SARS-CoV-2 during which he required mechanical ventilation. Chest x-rays revealed pneumothoraces, and bilateral chest tubes were inserted into the intrathoracic space for drainage five times. This case highlights the potential atypical clinical course in a COVID-19 infection and is the first reported case, to our knowledge, that features five bilateral spontaneous recurring pneumothoraces.

**Conclusion:** COVID-19-related pneumothorax is likely a sequela of COVID-19 disease progression due to the inflammatory insult from COVID-19 infection and the increased respiratory effort needed to maintain gas exchange. COVID-19-related pneumothoraces are associated with mechanical ventilation and resolved in prolonged hospitalization. The treatment of COVID-19 and its long-term consequences represents a relatively new challenge for clinicians and health care providers. A multidisciplinary approach during the posthospitalization management of COVID-19 survivors is strongly advised.

**Keywords:** SARS-CoV-2 infection, COVID-19 lung complications, pneumothorax

## INTRODUCTION

Coronavirus disease 2019 (COVID-19) is most frequently associated with a mild presentation of fever, cough, and shortness of breath, but COVID-19 can also present with respiratory complications.<sup>1</sup> Typical radiographic findings in severe COVID-19 infections are bilateral ground-glass opacities on computed tomography (CT) scans. Bilateral pneumothoraces are a rare complication of COVID-19.<sup>1,2,3</sup>

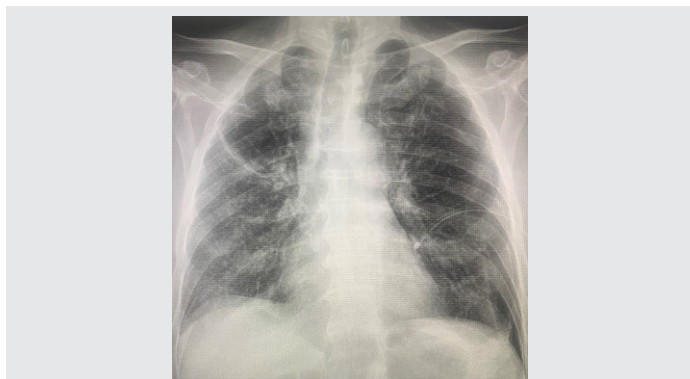
**Corresponding author:** Rosa Ragozzino

**Contact Information:** Rosaragozzino1990@gmail.com

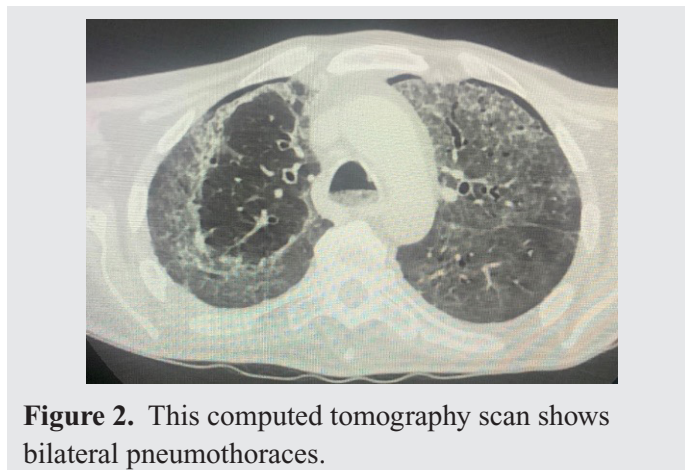
**DOI:** 10.12746/swrccc.v12i50.1259

## CASE

A 52-year-old man with no significant medical history presented with a week of dry cough and joint pain and had a positive COVID-19 PCR swab. He was admitted to the emergency room of the San Paolo Hospital in Civitavecchia, Italy, and was started on corticosteroids and 4 L/minute oxygen by face mask. A week later he was more hypoxemic and required oxygen supplementation with a high flow nasal cannula (HFNC). Three days later, he still had persistent hypoxemia and increased work of breathing, and he was intubated. The ventilator settings were respiratory rate 20 breaths per minute, tidal volume 400 ml, FiO<sub>2</sub> 50%, and positive end expiratory pressure 15 cm H<sub>2</sub>O.



**Figure 1.** This chest x-ray reveals bilateral small pneumothoraces.



**Figure 2.** This computed tomography scan shows bilateral pneumothoraces.

He underwent five prone-supine sessions, each lasting 12–18 hours.

However, due to the persistent hypoxemia, venous-venous extracorporeal membrane oxygenation (ECMO) became necessary. Extra corporeal membrane oxygenation was performed with a right jugular/right femoral approach, with initial settings as follows: blood flow 4.3 L/minute, sweep flow 4 L/minute, and  $\text{FiO}_2$  100%. Weaning from ECMO was successfully performed 9 days after this treatment was started. Later, the decision was made to proceed with percutaneous tracheostomy given prediction of prolonged intubation. He was weaned off the ventilator 20 days later and oxygen supplementation was started again with HFNC.

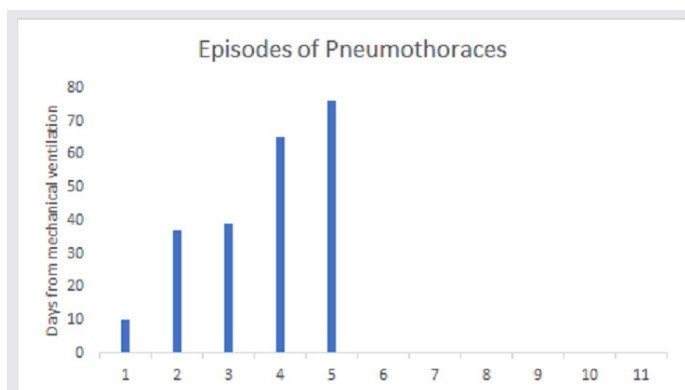
Due to a change in clinical status with an increase of neutrophils counts, the patient had a CT scan that showed a large right-sided pneumothorax and a left-sided pneumothorax (Figures 1 and 2). Chest tubes were placed in the intrathoracic spaces. After 14 days, his chest x-ray showed the resolution of the pneumothorax, and the chest tubes were removed. His oxygenation improved, and the patient was decannulated and started on oxygen supplementation using an HFNC. Then septic shock complicated the clinical course, and a chest x-ray showed a new right pneumothorax. The patient had a sudden desaturation, and an endotracheal tube was inserted again, and a second tracheostomy was performed. Two days later a left pneumothorax developed, and a left chest tube was placed.

The right chest tube was removed after seven days, and the left one after thirteen days. The patient

had three more episodes of recurrent bilateral pneumothorax; eventually chest x-rays showed the resolution of the pneumothoraces, and the chest tubes were removed (Figure 3). The patient was subsequently stable on room air, was decannulated, and was discharged to facility rehabilitation with close outpatient follow-up. To our knowledge this is the highest number of pneumothoraces related to SARS-CoV-2 infection reported (Figure 3).

## DISCUSSION

Patients with COVID-19 infection can develop severe pneumonia leading to acute respiratory distress syndrome (ARDS). Their disease is characterized



**Figure 3.** This figure plots the day of the development of bilateral pneumothoraces after the initial episode of mechanical ventilation.

radiographically by ground glass opacities, evolving into consolidative changes and, in late stages of the disease, fibrotic changes.<sup>4,5</sup> These changes, including severe lung injury and diffuse alveolar damage, probably contribute to the development of a pneumothorax complicating severe acute respiratory syndrome (SARS). These pathologic changes, in addition to possible overdistention of the alveoli by using mechanical ventilation, put patients at risk for developing pneumothorax.

In fact, mechanical ventilation appears to be a predominant risk factor for development of pneumothorax with COVID-19 pneumonia. This often happens in cases of high peak inspiratory pressures (greater than 40 to 50 cm H<sub>2</sub>O), high positive end-expiratory pressure, high tidal volumes, and minute ventilations.<sup>6,7,8</sup> Aiolfi and colleagues reported two cases of COVID-19 pneumonia in patients who developed persistent pneumothorax while on mechanical ventilation.<sup>8,9</sup>

Our patients developed his first pneumothorax ten days after weaning off the mechanical ventilation. The incidence of pneumothorax in mechanically ventilated patients is high, and is even higher in patients with ARDS, ranging between 14 to 87%. Acute respiratory distress syndrome has a heterogeneous pathology with a mixture of relatively healthy and diseased alveoli. Commonly, the dependent areas of the lung tend to consolidate due to interstitial edema and represent regions of decreased lung compliance. During lung recruitment maneuvers while managing ARDS, overdistention of “normal” non-dependent lung regions with relatively higher compliance and less airway resistance occurs. These alveoli then can rupture due to disproportionate distribution of volume and pressure from the ventilator causing increased shear forces.<sup>8</sup>

Other causes of the development of a pneumothorax as a sequela probably involve the pathophysiologic changes in COVID-19 infections. These changes include dysregulation of immune response, increased inflammation, and associated fibrosis that could contribute to the development of pneumothorax and pneumomediastinum independent of ventilator-induced barotrauma.<sup>8,10,11</sup> This is likely related to the development of diffuse alveolar damage seen in autopsies of deceased COVID-19 patients that

weakens the alveolar walls and produce dilated, cystic, and bullous airspaces (pneumatocele) in the lung parenchyma that rupture during intense coughing with sudden increases in intrathoracic pressure or with positive pressure ventilation. This mechanical trauma can cause an air leak into the pleura resulting in pneumothorax or into the bronchovascular bundles in the interstitium (Macklin effect) leading into the mediastinum (pneumomediastinum) with or without disrupting the mediastinal parietal pleural.<sup>1</sup>

The treatment of COVID-19 and its long-term consequences represents a relatively new challenge for clinicians and health care providers.<sup>1</sup> A multidisciplinary approach to posthospitalization management of COVID-19 survivors is strongly advised. A team of providers (pulmonologists, intensivists, pharmacists, advanced practice providers, nurses, physical and occupational therapists, respiratory therapists, social workers, case managers, and mental health providers) can diagnose and treat complications related to COVID-19 pneumonia. This comprehensive approach mirrors the magnitude of severe COVID-19 sequelae that can affect multiple domains of a patient's health. It is necessary to promote mind, body, social, and spiritual recovery in survivors of critical illness. Comprehensive ambulatory care for these vulnerable patients, also known as “long-haulers,” is imperative.<sup>12</sup>

---

**Article citation:** Ragozzino R, Risolia A, Martonea AM, Brandia V, Liperoti R, Landia F. COVID-19 infection with serial bilateral pneumothoraces. *The Southwest Respiratory and Critical Care Chronicles* 2024;12(50):41–44

**From:** Department of Geriatrics and Orthopaedics (RR, AR, AMM, VB, RL, FL), Fondazione Policlinico Universitario Agostino Gemelli IRCCS, Rome, Italy; Catholic University of Sacred Heart (AMM, VB, RL, FL), Rome, Italy. Department of Geriatrics and Orthopaedics, Rome, Italy

**Submitted:** 1/4/2024

**Accepted:** 1/15/2024

**Conflicts of interest:** none

This work is licensed under a Creative Commons Attribution-ShareAlike 4.0 International License.

---

**REFERENCES**

1. Chong WH, Saha BK, Hu K, et al. The incidence, clinical characteristics, and outcome of pneumothorax hospitalized COVID-19 patients: A systematic review. *Heart Lung* 2021 Sep–Oct;50(5):599–608.
2. Chen N, Zhou M, Dong X, et al. Epidemiological and clinical characteristics of 99 cases of 2019 novel coronavirus pneumonia in Wuhan, China: a descriptive study. *Lancet* 2020 Feb 15;395(10223):507–513.
3. Onder G, Rezza G, Brusaferro S. Case-fatality rate and characteristics of patients dying in relation to COVID-19 in Italy. *JAMA* 2020 May 12;323(18):1775–1776.
4. Yang F, Shi S, Zhu J, et al. Analysis of 92 deceased patients with COVID-19. *J Med Virol* 2020 Nov;92(11):2511–2515. doi: 10.1002/jmv.25891
5. Hosseiny M, Kooraki S, Gholamrezanezhad A, et al. Radiology perspective of coronavirus disease 2019 (COVID-19): lessons from severe acute respiratory syndrome and Middle East respiratory syndrome. *Am J Roentgenol* 2020;214:1078–82.
6. Albelda SM, Geftter WB, Kelley MA, et al. Ventilator-induced subpleural air cysts: clinical, radiographic, and pathologic significance. *Am Rev Respir Dis* 2015;127:360–5.
7. Woodside KJ, vanSonnenberg E, Chon KS, et al. Pneumothorax in patients with acute respiratory distress syndrome: pathophysiology, detection, and treatment. *J Intensive Care Med* 2003 Jan–Feb;18(1):9–20. doi: 10.1177/0885066602239120.
8. Zantah M, Castillo ED, Townsend R, et al. Pneumothorax in COVID-19 disease-incidence and clinical characteristics. *Respiratory Research* 2020 Sep 16;21(1):236.
9. Aiolfi A, Biraghi T, Montisci A, et al. Management of persistent pneumothorax with thoracoscopy and bleb resection in COVID-19 patients. *Ann Thorac Surg* 2020 Nov;110(5):e413–e415. doi: 10.1016/j.athoracsur.2020.04.011.
10. Elhakim TS, Abdul HS, Pelaez Romero C, et al. Spontaneous pneumomediastinum, pneumothorax and subcutaneous emphysema in COVID-19 pneumonia: a rare case and literature review. *BMJ Case Rep* 2020;13(12) doi: 10.1136/bcr-2020-239489.
11. Prompetchara E, Ketloy C, Palaga T. Immune responses in COVID-19 and potential vaccines: lessons learned from SARS and MERS epidemic. *Asian Pac J Allergy Immunol* 2020;38(1):1–9. doi: 10.12932/AP-200220-0772.
12. Attaway AH, Scheraga RG, Bhimraj A, et al. Severe COVID-19 pneumonia: pathogenesis and clinical management. *BMJ* 2021 Mar 10;372: n436. doi: 10.1136/bmj.n436.