

Drug-induced leukocytoclastic vasculitis: tigecycline a rare cause

Kalpna Bhairavarasu MD, Satish Mocherla MD, Jaya Amaram MD,
Ena Sharma MD, Philip A Conlin MD, Imran Umer MD

ABSTRACT

Drug-induced leukocytoclastic vasculitis is an inflammation of blood vessels triggered by various drugs. It presents with a localized skin rash but may involve the internal organ systems, including the gastrointestinal tract, kidneys, lungs, central nervous system, and joints. The clinical recognition of drug-induced vasculitis is very important because continued use of the culprit drug can be organ or life threatening. The prognosis is excellent if the disease is limited to the skin and diagnosed promptly. The use of tigecycline has recently increased due to resistance patterns of bacteria, and it is important to recognize this potential adverse effect of this drug and to diagnose and treat the patient early to achieve a favorable outcome. To best of our knowledge, we report the first case of tigecycline-induced leukocytoclastic vasculitis.

Key words: Drug-induced vasculitis, leukocytoclastic vasculitis, tigecycline-induced vasculitis, tigecycline related leukocytoclastic vasculitis

INTRODUCTION

Vasculitis is defined as an inflammatory disorder of blood vessels characterized by pathological change in the structure and function with resultant narrowing, weakening, and scarring of the blood vessel wall.¹ Drug-induced vasculitis is usually a small vessel vasculitis with leukocytoclastic vasculitis (LCV) histology. Antibiotics that commonly cause LCV include penicillins, aminopenicillins, sulfonamides, and quinolones.¹ To best of our knowledge, this is the first reported association of LCV with tigecycline.

CASE PRESENTATION

A 21-year-old man with a history of chronic left leg ulcer secondary to a motor vehicle accident with multiple skin grafts was admitted with painful swelling in both inguinal regions for three weeks. This was associated with fever and chills. There was no history of recent trauma, insect bites, or skin rash. His review of systems was unremarkable. Examination revealed a temperature 101 °F, heart rate 86 beats/minute, and respiratory rate 16/minute, and blood pressure 116/78 mmHg. He had bilateral enlarged tender inguinal lymph nodes soft to firm in consistency. His left leg had a 4 cm chronic ulcer with regular margins and no drainage. The rest of the physical examination was within normal limits. The patient was started on intravenous (IV) piperacillin/tazobactam for suspected sepsis. Later the piperacillin/tazobactam was switched to IV tigecycline on day five. An Infectious Disease consult broadened the empiric antibiotics

Corresponding author: Imran Umer MD
Contact Information: Imran.umer@ttuhsc.edu
DOI: 10.12746/swrccc2015.0309.123

coverage to include vancomycin and meropenem; tigecycline was continued. A fine needle aspiration of the inguinal lymph nodes was negative for malignancy, and an excisional biopsy of the inguinal lymph nodes showed chronic inflammation with no granulomas. On hospital day seven the patient started developing a new skin rash on both lower extremities which progressively worsened over the next 48 hours (Figure 1). A rheumatology consultation suspected vasculitis secondary to tigecycline after a thorough chart review. The patient was then started on systemic corticosteroids and colchicine, and on day nine tigecycline was discontinued. Extensive laboratory studies, including an immunologic workup with antinuclear antibodies (ANA), cytoplasmic antineutrophil cytoplasmic antibodies (C-ANCA), proteinase 3 (PR3) antibodies, myeloperoxidase (MPO) antibodies, anti-double-stranded DNA antibodies (Anti-dsDNA), were negative. A skin biopsy of the rash reported perivascular inflammatory cells with necrosis of vessel walls and deposition of fibrinoid material consistent with "leukocytoclastic vasculitis" (Figure 2). The patient's blood, sputum, and urine cultures were negative. On hospital day 11, his skin rash started resolving. Later the patient developed acute pericarditis with massive effusion on day 12. A cardiothoracic surgeon created a surgical window; the pericardial biopsy showed non-specific inflammatory cells. The patient had a complicated hospital course, and on day 30 he developed acute pancreatitis, a known adverse effect of tigecycline. Subsequently he developed multiorgan failure and did not survive.

DISCUSSION

LCV, also known as hypersensitivity vasculitis, is a relatively common condition. It can occur as a primary disorder or in association with drugs, infections, collagen-vascular diseases, hematologic disorders, and malignancy.² The American College of Rheumatology proposed criteria to define leukocytoclastic vasculitis which include: patient age greater than 16, use of a possible drug in temporal relation to symptoms, palpable purpura, maculopapular skin lesions, biopsy of a skin lesion showing neutrophils

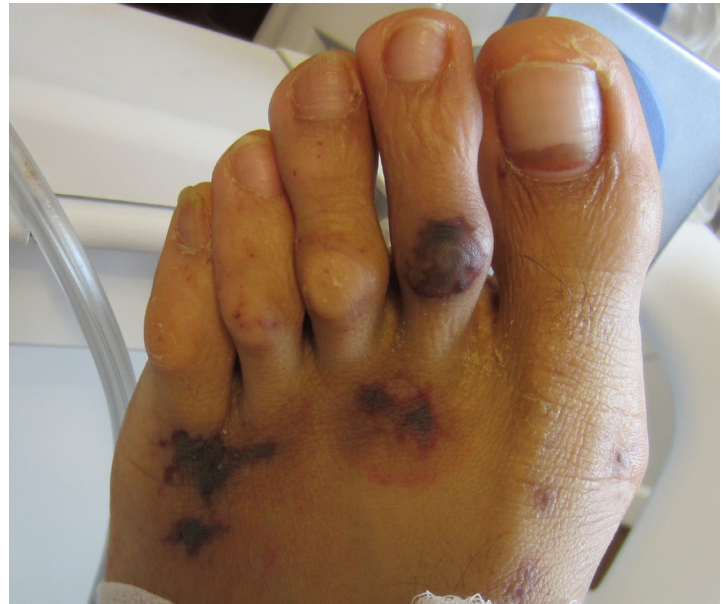

Figure 1 is a photograph of the macular purpuric rash on the left foot.

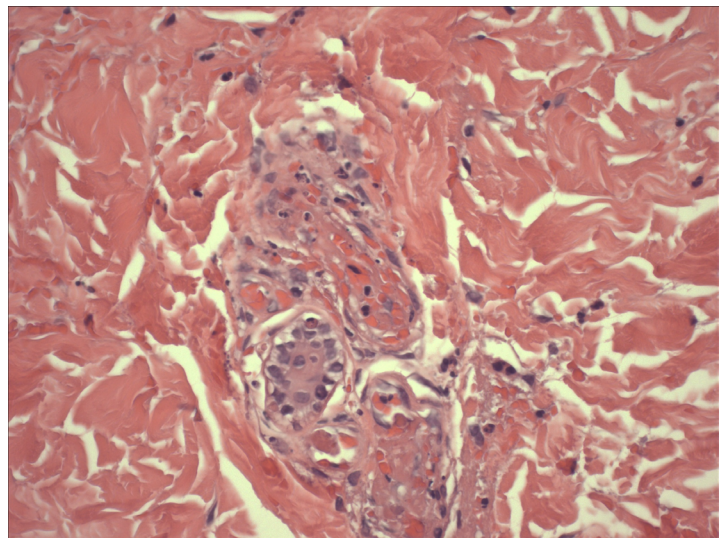


Figure 2 shows neutrophils infiltration around blood vessels with fibrinoid necrosis.

around arterioles or venules. At least three of five criteria must be present to diagnose LCV.³ Drug-induced LCV accounts about 10% of all vasculitis cases, and penicillins, sulfonamide, quinolones, allopurinol, propylthiouracil, valproic acid, phenytoin, anti-TNF alpha agents, and hydralazine are well known causes

of LCV.^{4,5} The exact pathogenesis of LCV is unclear. Drugs may act as haptens to stimulate immune responses and a cascade of inflammation involving small vessels with deposition of immune complex in the walls of arterioles and postcapillary venules. In most cases it is type III immune complex-mediated reaction.^{6,7}

The clinical manifestations of LCV vary from asymptomatic skin rashes to life threatening systemic involvement.⁸ It usually presents with a palpable purpuric or petechial skin rash involving the legs and can be associated with skin ulceration or edema. LCV can also involve internal organs, including the gastrointestinal tract, kidneys, lungs, central nervous system, and joints, and can be fatal.⁹⁻¹¹ The prognosis is excellent if the disease is limited to skin and diagnosed promptly. The diagnosis of drug-induced LCV is sometimes challenging. However, the pattern of development and resolution of the skin lesions with discontinuation of culprit drugs can help in diagnosis. Drug-induced LCV should be suspected in any patient with small vessel vasculitis. For an exact diagnosis, history and examination, a temporal relationship with the offending drug(s), and exclusion of other potential causes are required.¹² Biopsy of skin lesions for histopathology and examination under immunofluorescence are the gold standard.⁵ Perivascular inflammatory cell invasion with necrosis of the vessel wall and with deposition of fibrinoid material is pathognomonic for leukocytoclastic vasculitis (Figure-2). This was seen in our case.¹³

Management of LCV requires treatment of the underlying cause, discontinuation of suspected medications, and topical treatment of skin lesions with corticosteroids. Systemic agents, such as potent corticosteroids, colchicine, dapsone, nonsteroidal anti-inflammatory drugs, potassium iodide, antihistamines, immunosuppressive agents and rarely monoclonal antibodies are used, depending on the severity of the systemic vasculitis.¹⁰ Drug-induced LCV often resolves with discontinuation of the culprit on drug.¹⁴

Tigecycline is a tetracycline derivative commonly used to treat complicated skin and soft tissue

infections. Reports of tetracycline derivative (e.g., minocycline) induced autoimmunity include drug-induced lupus, cutaneous polyarteritis nodosa, and anti-nuclear cytoplasmic antibody (ANCA)-associated vasculitis.¹⁵ In our patient, tigecycline was the probable cause of LCV, and this is the first reported case to our knowledge. Forty-eight hours after the discontinuation of tigecycline, the patient's skin lesions started improving; after four days they resolved completely. Later the patient developed fatal pancreatitis (a well known side-effect of tigecycline) with multiorgan failure from which he did not survive.

In summary, drug-induced LCV should be suspected in any patient with a new onset skin rash, a temporal relationship with the offending drug, and resolution of symptoms with discontinuation of the drug. Physician should know that tigecycline-induced LCV is one of the rare side effects of this medication.

Author Affiliation: Kalpana Bhairavarasu is a faculty member in Rheumatology at Texas Tech University Health Sciences Center in Odessa, TX. Jaya Amaram, Ena Sharma, and Imran Umer are residents in Internal Medicine at TTUHSC in Odessa, TX. Satish Mocherla is a clinical assistant professor in Infectious Disease at TTUHSC in Odessa, TX. Philip A Conlin is a pathologist at DX Laboratories in Midland, TX.

Received: 10/23/2014

Accepted: 01/02/2015

Reviewers: Anoop Nambiar MD

Published electronically: 01/15/2015

Conflict of Interest Disclosures: none

REFERENCES

1. Jennette JC, Falk RJ. Small-vessel vasculitis. *N Engl J Med* 1997; 337:1512-23.
2. Lotti T, Ghersetich I, Comacchi C, Jorizzo JL. Cutaneous small-vessel vasculitis. *J Am Acad Dermatol* 1998; 39:667-87.

3. Hunder, GG, Arend WP, Bloch DA, Calabrese LH, Fauci AS, Fries JF, *et al.* Am Coll Rheum 1990 criteria for the classification of vasculitis. *Arthritis Rheum* 1990; 33:1135-6.
4. Ha YJ, Han YJ, Choi YW, Myung KB, Choi HY. Sibutramine induced cutaneous leukocytoclastic vasculitis: A case report. *Ann Dermatol* 2011; 23:544-7.
5. Lasić D, Ivanišević R, Uglešić B, Cvitanović MZ, Glučina D, Hlevnjak I. Valproate-acid induced cutaneous leukocytoclastic vasculitis. *Psychiatr Danub* 2012; 24(2):215-8.
6. Van Rosum AP, Pas HH, Fazzini F, Huitema MG, Limburg PC, Jonkman MF, *et al.* Abundance of the long pentraxin PTX3 at sites of leukocytoclastic lesions in patients with small-vessel vasculitis. *Arthritis Rheum* 2006; 54:986-91.
7. Mullick FG, McAllister HA Jr, Wagner BM, Fenoglio JJ Jr. Drug related vasculitis. Clinico- pathologic correlations in 30 patients. *Hum Pathol* 1979; 10:313-25
8. Jessop SJ. Cutaneous leukocytoclastic vasculitis: a clinical and etiological study. *Brit J Rheum* 1995; 34(10):942-5.
9. Roujeau JC, Stern RS. Severe adverse cutaneous reactions to drugs. *N Engl J Med* 1994; 331:1272-85.
10. Dubost JJ, Souteyrand P, Sauvezie B. Drug-induced vasculitides. *Baillieres Clin Rheum* 1991; 5:119-38
11. Jain KK. Drug-induced cutaneous vasculitis. *Adverse Drug React Toxicol Rev* 1993; 12:263-76
12. Wiik A. Drug-induced vasculitis. *Curr Opin Rheum* 2008; 20:35-9.
13. Carlson JA, Ng BT, Chen KR. Cutaneous vasculitis update: diagnostic criteria, classification, epidemiology, etiology, pathogenesis, evaluation and prognosis. *Am J Dermatopathol* 2005; 27:504-528.
14. Maunz G, Conzett T, Zimmerli W. Cutaneous vasculitis associated with fluoroquinolones. *Infection* 2009; 37(5):466-8.
15. Kermani TA, Ham EK, Camilleri MJ, Warrington KJ. Polyarteritis nodosa-like vasculitis in association with minocycline use: a single-center case series. *Semin Arthritis Rheum* 2012; 42(2):213-21.