

Extensive hepatic portal venous air in acute mesenteric ischemia

MA Orellana-Barrios MD, D Sotello MD, R Medrano MD

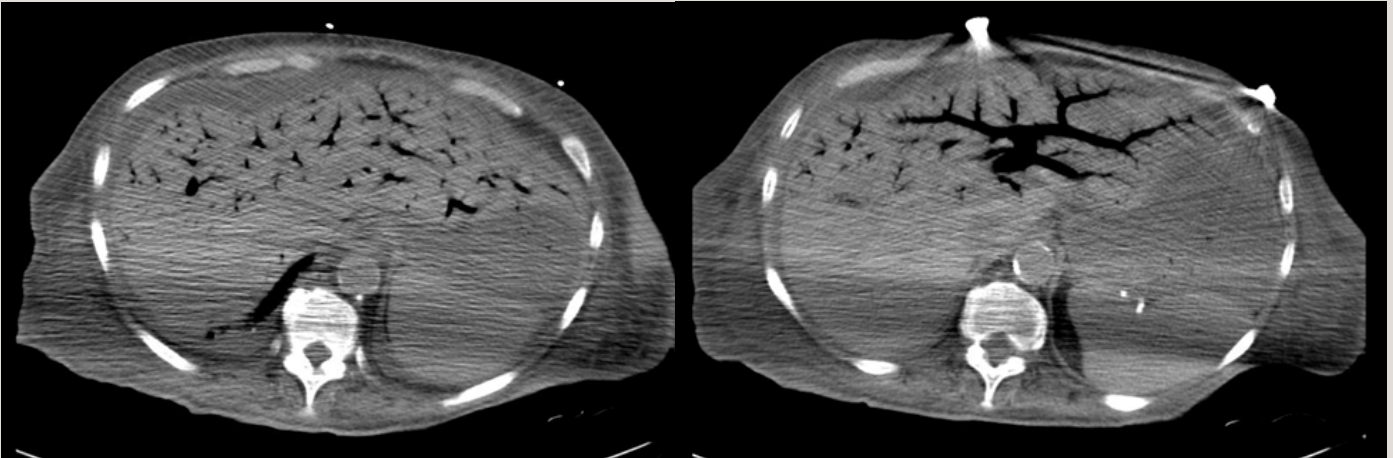


Figure 1-2. CT scans showing extensive gas within the hepatic portal venous system.

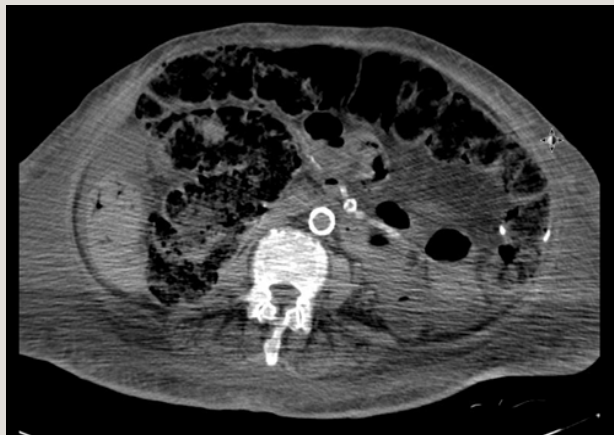

Figure 3. CT abdomen showing extensive vessel calcification, bowel dilatation, wall edema, and pneumatosis intestinalis

CASE

A 73-year-old-woman presented with acute onset, severe (10/10), generalized abdominal pain associated with nausea and “coffee ground” emesis. The pain

had been constant since onset approximately two hours before presentation. Her past medical history included hypertension, hyperlipidemia, diabetes mellitus type 2, peripheral arterial disease with bilateral subclavian stent placement, ESRD on hemodialysis, mild dementia, and depression. Current medications were quetiapine, amlodipine, simvastatin, aspirin, and sevelamer.

Corresponding author: Menfil Orellana-Barrios
Contact Information: ma.orellana-barrios@ttuhsc.edu
DOI: 10.12746/swrccc 2015.0310.133

Physical examination: blood pressure 128/54 mmHg, heart rate 82 beats per minute, respiratory rate 20 breaths per minute, and room air O₂ saturation 90%. The patient was in moderate distress. Her abdomen was distended and rigid with decreased bowel sounds.

Initial laboratory values: hemoglobin 11.2 g/dL, hematocrit 34.8%, leukocytes 4.4K/ μ L, platelets 172K/ μ L, BUN 27 mg/dL, creatinine 1.7 mg/dL, CO₂ 28 meq/L, glucose 137 mg/dL, Na 134 mEq/L, K 3.2 mEq/L, Ca 9.0 mg/dL, total bilirubin 2.9 mg/dL, AST 102 IU/L, alkaline phosphatase 248 IU/L, amylase 20 IU/L, lactic Acid 1.2 mmol/L. ECG showed atrial fibrillation with a heart rate in the 80s.

A computed tomography (CT) scan of the abdomen showed a distended small bowel with *pneumatosis intestinalis*, highly suggestive of bowel ischemia leading to necrosis. Extensive air in the portal venous system was present, mainly in the left hepatic lobe (Figure 1). The patient developed refractory shock despite resuscitation with IV fluids and vasopressor therapy. Surgical consultation was sought, but the patient and family decided to focus on comfort care. She died 4.5 days after symptom onset.

DISCUSSION

Acute mesenteric ischemia (AMI) is an uncommon urgent medical condition, almost always occurring in patients with significant cardiovascular comorbidities. Without surgical treatment, the mortality of acute mesenteric ischemia ranges from 87.1% to 99.4%, depending on the exact etiology (arterial embolism, arterial thrombosis, venous thrombosis, or non-occlusive mesenteric ischemia).¹

CT scans of the abdomen with angiography have become the “new gold standard” in the early diagnosis of gastrointestinal ischemic injuries and are now recommended as the first imaging approach in patients with AMI. CT scan imaging has the advantage of showing both vascular and nonvascular

findings associated with AMI.² Hepatic portal venous gas (HPVG) is the presence of gas within the portal vein and its intrahepatic branches. The mechanism by which this occurs is not definitely known, since several conditions are associated with its occurrence. Some are lethal, and some are benign. Necrotic bowel is the main etiology in >70% of HPVG in adults.³ Necrotizing enterocolitis is a common cause of HPVG in children; HPVG is associated with particularly severe presentations or with *Clostridium perfringens* infections.⁴⁻⁷

Our case illustrates the association of multiple preexisting cardiovascular risk factors, ESRD, undiagnosed atrial fibrillation, and acute mesenteric ischemia. The computed tomography scan images in Figures 1-3 show some diffuse vascular calcification and some nonvascular findings of AMI, including bowel wall thickening, bowel dilatation, pneumatosis intestinalis, and HPVG. It is important to differentiate HPVG from pneumobilia, also called aerobilia. The latter tends to occur more centrally in the liver than HPVG, as the flow of bile is toward the liver hilum. Air in the gallbladder should also suggest that air within the liver parenchyma has traveled via the biliary system. Although the images may be quite similar, pneumobilia is not associated with mesenteric ischemia.⁸

Classically thought of as an “ominous radiologic sign,”^{9,10} HPVG has been historically associated with 75 to >90% acute mortality in the setting of abdominal pain and acute mesenteric ischemia.³ However, some recent case reports have shown that HPVG can be also present in transient conditions with much lower acute mortality, such as Crohn’s disease¹¹, gastric dilatation^{12,13} viral gastroenteritis¹⁴ and uncomplicated endoscopic procedures.^{15,16} The recent decrease in overall mortality of HPVG is associated with higher detection in benign conditions.¹⁷ The radiologic characteristics of HPVG on ultrasound may aid in determining the outcome of patients with HPVG, as dot-like patterns are associated with benign outcomes and streak or fruit-pulp like patterns are associated with poor outcomes.¹⁸

Author affiliations : Menfil Orellana-Barrios and Davis Sotelo are residents in Internal Medicine at Texas Tech University Health Sciences Center in Lubbock, TX. Rita Medrano is a research assistant in the TTUHSC Department of Internal Medicine in Lubbock.

Submitted: 3/15/2015

Accepted: 4/3/2015

Reviewers: Tinsay Woreta MD

Conflict of Interest: None

Published electronically: 4/15/2015

References

1. Schoots IG, Koffeman GI, Legemate DA, Levi M, van Gulik TM. Systematic review of survival after acute mesenteric ischaemia according to disease aetiology. *Br J Surg* 2004;91(1):17-27.
2. Oliva IB, Davarpanah AH, Rybicki FJ, et al. ACR Appropriateness Criteria (R) imaging of mesenteric ischemia. *Abdom Imaging* 2013;38(4):714-719.
3. Liebman PR, Patten MT, Manny J, Benfield JR, Hechtman HB. Hepatic--portal venous gas in adults: etiology, pathophysiology and clinical significance. *Ann Surg* 1978;187(3):281-287.
4. Arnon RG, Fishbein JF. Portal venous gas in the pediatric age group. Review of the literature and report of twelve new cases. *J Pediatr* 1971;79(2):255-259.
5. Kennedy J, Holt CL, Ricketts RR. The significance of portal vein gas in necrotizing enterocolitis. *Am Surg* 1987;53(4):231-234.
6. Molik KA, West KW, Rescorla FJ, Scherer LR, Engum SA, Grosfeld JL. Portal venous air: The poor prognosis persists. *Journal of Pediatric Surgery* 2001;36(8):1143-1145.
7. Dittmar E, Beyer P, Fischer D, et al. Necrotizing enterocolitis of the neonate with *Clostridium perfringens*: diagnosis, clinical course, and role of alpha toxin. *Eur J Pediatr* 2008;167(8):891-895.
8. Sherman SC, Tran H. Pneumobilia: Benign or life-threatening. *The Journal of Emergency Medicine* 2006;30(2):147-153.
9. Khalaf N, Mittal S. Hepatic portal venous gas: an ominous sign of mesenteric ischemia. *Clin Gastroenterol Hepatol* 2014;12(6):xxix-xxx.
10. Abboud B, El Hachem J, Yazbeck T, Doumit C. Hepatic portal venous gas: physiopathology, etiology, prognosis and treatment. *World J Gastroenterol* 2009;15(29):3585-3590.
11. Delamarre J, Capron JP, Dupas JL, Deschepper B, Jouet-Gondry C, Rudelli A. Spontaneous portal venous gas in a patient with Crohn's ileocolitis. *Gastrointest Radiol* 1991;16(1):38-40.
12. Bani-Hani KE, Heis HA. Iatrogenic gastric dilatation: a rare and transient cause of hepatic-portal venous gas. *Yonsei Med J* 2008;49(4):669-671.
13. Allaparthi SB, Anand CP. Acute gastric dilatation: a transient cause of hepatic portal venous gas-case report and review of the literature. *Case Rep Gastrointest Med* 2013;2013:723160.
14. Mirmanesh M, Nguyen QS, Markelov A. A case of hepatic portal venous gas due to viral gastroenteritis. *Hepat Med* 2013;5:63-65.
15. Kuo SM, Chang WK, Yu CY, Hsieh CB. Silent hepatic portal venous gas following upper gastrointestinal endoscopy. *Endoscopy* 2009;41 Suppl 2:E121-122.
16. Salyers WJ, Jr., Mansour A. Portal venous gas following colonoscopy and small bowel follow-through in a patient with Crohn's disease. *Endoscopy* 2007;39 Suppl 1:E130.
17. Nelson AL, Millington TM, Sahani D, et al. Hepatic portal venous gas: the ABCs of management. *Arch Surg* 2009;144(6):575-581; discussion 581.
18. Pan HB, Huang JS, Yang TL, Liang HL. Hepatic portal venous gas in ultrasonogram--benign or noxious. *Ultrasound Med Biol* 2007;33(8):1179-1183.