

Tracheal Stenosis

Colbert Perez MD , Ralph Paone MD, and Raed Alalawi MD

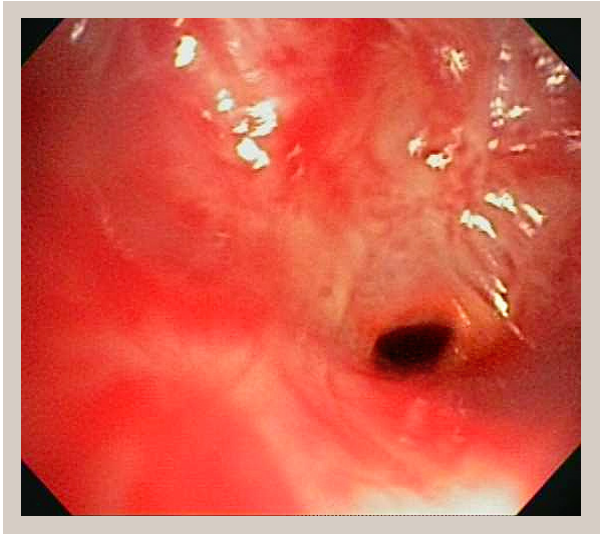


Figure 1 Initial bronchoscopy demonstrating tracheal stenosis with an airway size of 2-4 mm.

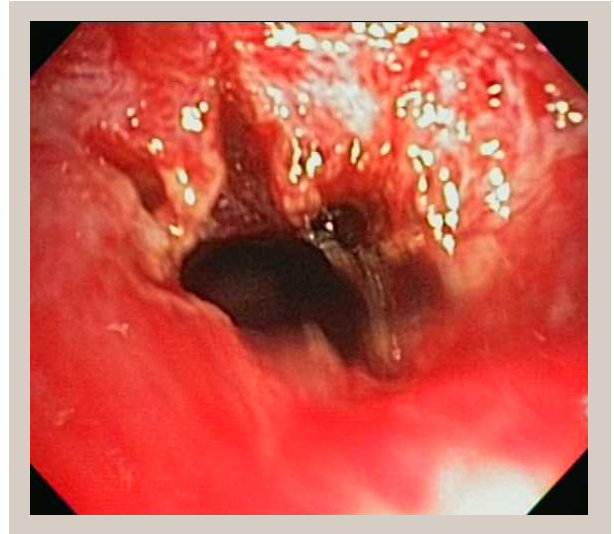


Figure 2 After balloon dilation with 15 mm balloon and an approximate airway size of 10 mm.

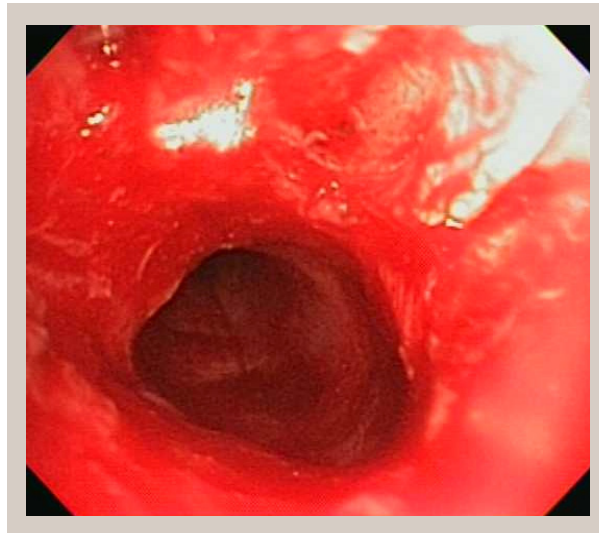


Figure 3 After Endoscopic electrocauterization and balloon dilation

A 43-year-old woman with a history of asthma presented with five months of worsening dyspnea unresponsive to her current asthma therapy. Her

symptoms began one month after an asthma exacerbation that was complicated by pneumonia and required intubation. Upon arrival her oxygen saturations were 79%, and she had significant stridor and respiratory distress. A non-rebreather mask was required to maintain oxygen saturations above 90%. After being placed on a 70/30 heliox mixture, her work of breathing greatly improved. Bronchoscopy and endoscopic treatment relieved her dyspnea (Figures 1-3).

Corresponding author: Colbert Perez

Contact Information: colbert.perez@
ttuhsc.edu

DOI: 10.12746/swrccc 2013.0102.019

Adult tracheal stenosis secondary to intubation has a reported incidence of 0.6-21% and is presumed to be related to cuff injury in 31% of cases (1). It may take 30 days to develop after extubation, and the diagnosis is best made by bronchoscopy (2). However, helical CT with reconstruction has 93% sensitivity and 100% specificity (3). Heliox mixtures can reduce the work of breathing in the acute setting and helped in this case. The low density of heliox reduces turbulent airflow which decreases airway resistance, pleural pressure swings, and dynamic hyperinflation (4). The best treatment for adult tracheal stenosis is endobronchial laser resection, but complex lesions may require surgical resection and/or stents.

Received: 3/19/13

Revised: 3/22/13

Accepted: 3/25/13

Published online: 4/16/13

Reviewers: Kenneth Nugent MD

Conflict of Interest Disclosures: None

References

1. Grillo HC. Management of nonneoplastic diseases of the trachea. In: Shields TW, LoCicero J III, Ponn RB, editors. General thoracic surgery. Vol 1. 5th ed. Philadelphia: Lippincott Williams & Wilkins; 2000. p. 885–97.
2. Sarper A, Aytan A, Eser I, et al. Tracheal stenosis after tracheostomy or intubation: review with special regard to cause and management. *Tex Heart Inst J* 2005; 32:154–158.
3. Herrera P, Caldarone C, Forte V, et al. The current state of congenital tracheal stenosis. *Pediatr Surg Int* 2007; 23:1033–44.
4. Feller-Koppman D, Odonnel C. Physiology and clinical use of heliox. UptoDate. Waltham, MA, 2013.